

Physical Assessment & the Pathofunctional Diagnosis



How a physical therapy assessment can augment veterinary diagnostics

LAURIE EDGE-HUGHES,
B.SC.PT, M.ANIM.ST(ANIMAL PHYSIO.), CAFCI, CCRT
THE CANINE FITNESS CENTRE LTD, CALGARY, CANADA
THE CANINE REHAB INSTITUTE, FLORIDA & COLORADO
THE ANIMAL REHAB DIVISION OF THE CPA

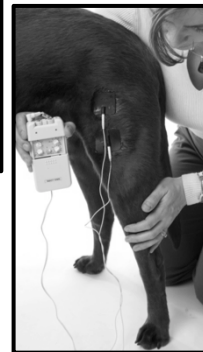
Physical Therapy Assessments in Vet Medicine



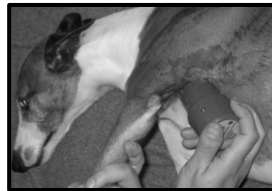- Underwater Treadmills



- Hypoallergenic Gel



- Therapy Balls



- Lasers

- Electrodes

Physical Therapy Assessments in Vet Medicine



- **Success in rehab**
 - Depends upon an accurate physical diagnosis.
- **What physical therapists bring to the veterinary field**
 - MORE manual assessment techniques
 - Enhanced deductive reasoning skills
 - Evaluation of function



Physical Therapy Assessments in Vet Medicine



- **Patho-anatomical diagnosis:**
 - This diagnostic perspective seeks the anatomical origination of the 'problem'
 - Relying some on clinical tests, and heavily on diagnostic tests.
 - The primary goal is to 'name the lesion',
 - With the subsequent thought process being 'how to reduce the lesion.'

Physical Therapy Assessments in Vet Medicine


• **Patho-functional diagnosis:**

- This diagnostic perspective not only seeks the anatomical origination of the ‘problem’
- Utilizing an assessment algorithm and the cumulative results from clinical tests
- But also identifies the functional impairment, inter-relationships with other structures, repercussions, and potential biomechanical origins of the lesion.
- Thus the subsequent goal or thought process is not only ‘how to best reduce the lesion’ (perhaps by rehabilitative treatments, or by referral for surgery, etc)....
 - ✦ but also how to improve function.

Physical Therapy Assessments in Vet Medicine

• **Case Example** – KASH – 12 yo MN Border Collie x Blk Lab


- Referring Dx:
 - ✦ “Decreased ROM in hips due to arthritis secondary to dysplasia”
- Treatments to date:
 - ✦ K-Laser to hips
 - ✦ Cartrophen & Metacam
 - ✦ Joint-diet food
- Activity level
 - ✦ Off-leash 3x / day
 - ✦ (Total 1 – 1.5 hrs/day)



Physical Therapy Assessments in Vet Medicine



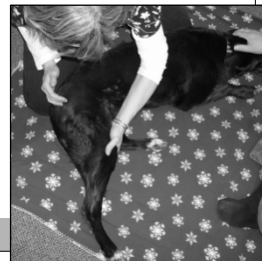- **Case Example** – KASH – 12 yo MN Border Collie x Blk Lab
 - Subjective History
 - ✦ Known hip dysplasia R worse than L
 - ✦ 3 months ago began limping on LF
 - Swelling of the toes on LF
 - ✦ Aggravating factors:
 - Increased play... Will cause a dragging of RH
 - Worse at the end of the day
 - Metacam helps
 - Owner concerned about front leg issues



Physical Therapy Assessments in Vet Medicine



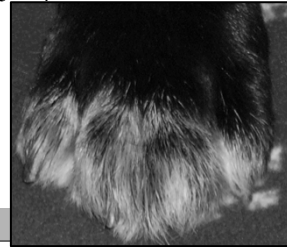- **Case Example** – KASH – 12 yo MN Border Collie x Blk Lab
 - Pathofunctional Assessment Findings
 - ✦ Hips: (bilaterally)
 - Reduced extension with 'hard' end feel but NO pain with ROM
 - R = 130° L = 145°
 - NO pain with palpation of pectineus,
 - MILD pain on palpation of deep gluteal muscles
 - NO pain with palpation of iliopsoas muscles
 - RH - tenderness on palpation of sartorius
 - ✦ Sacroiliac Joint & Lumbar Spine
 - No tenderness
 - Hard boney end feels to test movements



Physical Therapy Assessments in Vet Medicine



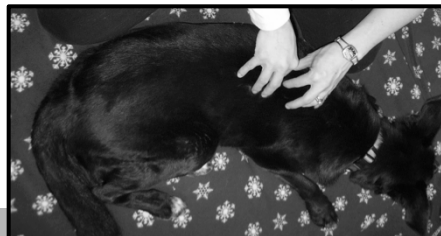- **Case Example** – KASH – 12 yo MN Border Collie x Blk Lab
 - Pathofunctional Assessment Findings
 - FORELIMBS
 - ✦ L Shoulder, Elbows, & Carpi (bilat.)= Full ROM, NO tenderness
 - ✦ R Shoulder =
 - Discomfort & apprehension at end ROM flex, ext, abd.
 - Discomfort with palpation of Teres Major / Lat Dorsi
 - ✦ Digits (bilaterally)
 - Thickening at MCPs 2 – 5
 - Discomfort to fully flex & extend these joints



Physical Therapy Assessments in Vet Medicine



- **Case Example** – KASH – 12 yo MN Border Collie x Blk Lab
 - Pathofunctional Assessment Findings
 - ✦ The REST of the Spine
 - Cervical: Full ROM, Good Mobility, NO tenderness
 - Thoracic:
 - VERY tender T8 – T11 + associated ribs
 - MILD tenderness T1 - 7



Physical Therapy Assessments in Vet Medicine

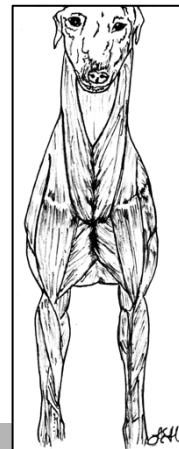


- **Case Example** – KASH – 12 yo MN Border Collie x Blk Lab
 - Pathofunctional DIAGNOSIS
 - ✦ “I think the hip osteoarthritis and (suspected) fusion of the sacroiliac joints & Lumbar spine are only causing MECHANICAL issues but minimal soft tissue / nervous system reactions”
 - ✦ Painful areas seem to be:
 - The forepaw digits (R > L MCP joints) – (suspected OA)
 - T8 – T11 (and associated ribs) – (suspected overuse)
 - The Right shoulder - (suspected OA)
 - Teres Major / Lat Dorsi – (suspected overuse)
 - ✦ Due to the postural & movement compensations (secondary to the hips / caudal spine).

Physical Therapy Assessments in Vet Medicine



- **Thinking outside the box to ‘name the lesion’**
 - Several non-traditional sites and lesions can result in lameness, poor movement, reduced athletic performance, and postural alterations.
 - Examples in MUSCLE
 - ✦ Muscle strains
 - ✦ Tendinopathies
 - ✦ Muscle weakness
 - ✦ Muscle shortening
 - ✦ Muscle over-activity
 - ✦ Myofascial trigger points



Physical Therapy Assessments in Vet Medicine



• Thinking outside the box to ‘name the lesion’

○ **Muscle Strain** – Example Teres Major

- Edge-Hughes L. Anatomy, biomechanics, physiology, diagnosis and treatment of teres major strains in the canine. Third International Symposium on Rehabilitation and Physical Therapy in Veterinary Medicine, Research Triangle, North Carolina, 2004.
 - ✦ 14 athletic dogs: 5 female, 9 male; 2 yrs – 10 yrs
 - ✦ Front limb lameness, referred with ‘open diagnoses’
 - 8 / 14 had x-rays revealing Normal shoulder joint
 - ✦ Vet Rx: rest (all cases), NSAIDs (1/2 of cases)
 - ✦ Onset of lameness varied 2 day – 2 years
 - ✦ Physical exam: pain to stretch & pain on palpation of T.Maj.
 - 4 had no other finding, 10 had secondary findings

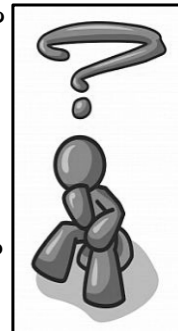
Physical Therapy Assessments in Vet Medicine



• Thinking outside the box to ‘name the lesion’

○ **Muscle Strain** – Example Teres Major

- Edge-Hughes L. Anatomy, biomechanics, physiology, diagnosis and treatment of teres major strains in the canine. Third International Symposium on Rehabilitation and Physical Therapy in Veterinary Medicine, Research Triangle, North Carolina, 2004.
 - ✦ Need to think about:
 - What is the Origin & Insertion of Teres Major?
 - What is the action of Teres Major?
 - How does it become injured?
 - How do you assess for it?
 - ✦ Therapeutic Considerations
 - What are your treatment goals?
 - What are the principles for soft tissue healing?
 - How do you stage return to activity?




Physical Therapy Assessments in Vet Medicine

- Thinking outside the box to ‘**name the lesion**’

- **Muscle Strain** – Example Teres Major

- Edge-Hughes L. Anatomy, biomechanics, physiology, diagnosis and treatment of teres major strains in the canine. Third International Symposium on Rehabilitation and Physical Therapy in Veterinary Medicine, Research Triangle, North Carolina, 2004.



Physical Therapy Assessments in Vet Medicine

- Thinking outside the box to ‘**name the lesion**’

- **Muscle weakness**

- ✦ Reduced joint cushioning
 - I.E. weak quadriceps & hamstring muscle groups with stifle osteoarthritis
- ✦ Improper biomechanics
 - I.E. weak abdominal muscles with lumbosacral pain and dysfunction
- ✦ May lead to abnormal joint development
 - I.E. possible rationale for unilateral hip dysplasia
- TREATMENTS:
- Exercise must be specific and targeted to see improvement!

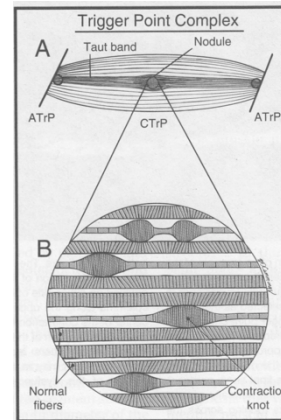
Physical Therapy Assessments in Vet Medicine



- Thinking outside the box to ‘**name the lesion**’
 - **Myofascial Trigger Points**

“...a hyper-irritable spot in skeletal muscle that is associated with a hypersensitive palpable nodule in a taut band. The spot is tender when pressed, and can give rise to characteristic referred pain, motor dysfunction, and autonomic phenomena...”

(Simons, Travell, & Simons 1999)



Physical Therapy Assessments in Vet Medicine



- Thinking outside the box to ‘**name the lesion**’
 - **Myofascial Trigger Points**

✦ Development of Myofascial Trigger Points:

- Persistent low-level muscle contractions (Cinderella theory)
- Uneven intramuscular pressure distribution
- Direct trauma
- Unaccustomed eccentric contractions / eccentric contractions in unconditioned muscle
- Maximal or submaximal concentric contractions

Physical Therapy Assessments in Vet Medicine

- **Case Example** – Trace - 5 yo - FS Flat-Coated Retriever

- Referring Dx:

- ✦ “Progressive hind limb lameness with questionable osteoarthritis”
- ✦ “Patella Alta’

- Treatments to date:

- ✦ Metacam (as needed)
- ✦ Glucosamine (human brand)

- Activity level

- ✦ Long walks (45 min – 1 hour / day)
- ✦ Chasing balls, & Swimming in river



Physical Therapy Assessments in Vet Medicine

- **Case Example** – Trace - 5 yo - FS Flat-Coated Retriever

- Diagnostic tests:

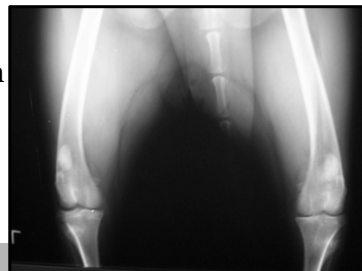
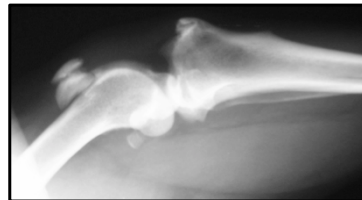
- ✦ X-rays of spine, hips, & stifles

- Subjective Hx:

- ✦ “Running a little odd” x 3 months

- Surgical consult:

- ✦ Patella Alta
- ✦ Owner offered surgery to lengthen the sartorius muscle



Physical Therapy Assessments in Vet Medicine

- **Case Example** – Trace - 5 yo - FS Flat-Coated Retriever

- Pathofunctional Assessment Findings

- ✦ Posture & Limb Evaluations

- Reduced weight bearing on RH in stance

- Proximal thigh circumference L = 41cm & R = 39.5cm

- ✦ **STIFLES**

- Flexion of stifles (with hips in extension):

- L = 105° & R = 130° (less flexion)

- Coarse crepitus at patellofemoral joints with stifle ROM (bilaterally)

- R sartorius very tight on palpation

- R sartorius tender on palpation



Physical Therapy Assessments in Vet Medicine

- **Case Example** – Trace - 5 yo - FS Flat-Coated Retriever

- Pathofunctional Assessment Findings

- ✦ Secondary Issues:

- Left Sacroiliac joint dysfunction

- Moderate tenderness teres major (bilaterally)



Physical Therapy Assessments in Vet Medicine



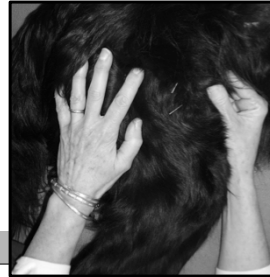- **Case Example** – Trace - 5 yo - FS Flat-Coated Retriever

- Pathofunctional Diagnosis:

- ✦ Myofascial trigger points and tightness of the right sartorius
- ✦ This may be causing additional compressive forces at the patellofemoral joint(s) – and the subsequent crepitus

- ✦ **Treatment NOTE:** Treatment of the trigger points resolved the signs completely

- Laser
- Dry Needling
- Stretches



Physical Therapy Assessments in Vet Medicine



- Thinking outside the box to ‘**name the lesion**’

- **Axial Skeleton Dysfunctions**

- ✦ Skull (i.e. TMJ), Spine, Ribs, and Pelvis (i.e. SIJ)
- ✦ Dysfunction: a physiotherapy term that implies that a joint is not moving appropriately, and is either termed as hypomobile or hypermobile
- ✦ Signs:
 - Localized pain on palpation
 - Pain down a limb / lameness / gait abnormalities
 - Reduced athletic performance / functional performance

Physical Therapy Assessments in Vet Medicine

• **Case Example** – Ursula – 2 yo – F - Borzoi

- Referring Diagnosis:
 - ✦ No Significant Findings at time of exam.
 - ✦ 1 week history of yelping when getting up from lying.
 - ✦ Further diagnostics declined by owner
- Treatments to Date:
 - ✦ Reduced activity
- Activity Level:
 - ✦ Plays with other dogs.
 - ✦ “Very hard on her body.”



Physical Therapy Assessments in Vet Medicine

• **Case Example** – Ursula – 2 yo – F - Borzoi

- Pathofunctional Assessment:
 - ✦ Posture / Gait
 - No lameness
 - Not off-loading of any limb
 - ✦ Extremity Joints & Soft Tissues
 - Full ROM & NO tenderness on palpation throughout forelimbs
 - Full ROM & NO tenderness on palpation of digits, tarsi, & stifles
 - HIPS
 - Pain on deep palpation of iliopsoas muscles bilaterally



Physical Therapy Assessments in Vet Medicine

- **Case Example** – Ursula – 2 yo – F - Borzoi

- Pathofunctional Assessment:

- ✦ **The Spine**

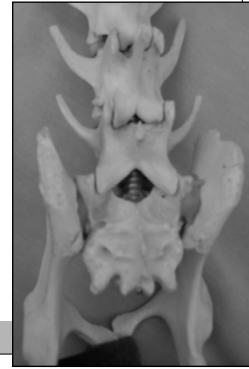- Cervical spine & Thoracic spine: Good mobility. No tenderness

- **Lumbar spine:**

- Very tender at L7
- Atrophy / Hypotonicity of the epaxials & multifidus muscles adjacent to L6 – S1
- Pain to 'close down' Left facet of L7/S1

- **Pelvis**

- Bilateral tenderness over SIJ & Piriformis
- Right ilium positionally cranial.



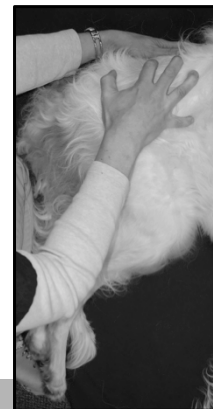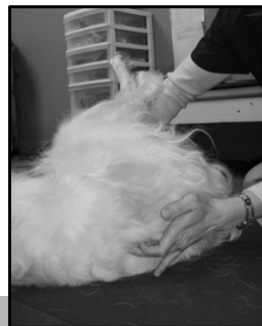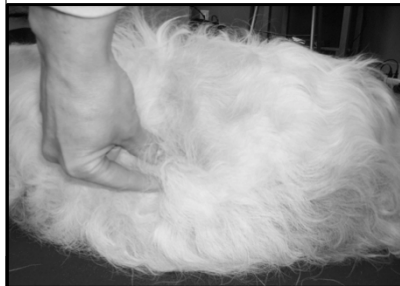Physical Therapy Assessments in Vet Medicine

- **Case Example** – Ursula – 2 yo – F - Borzoi

- Pathofunctional DIAGNOSIS

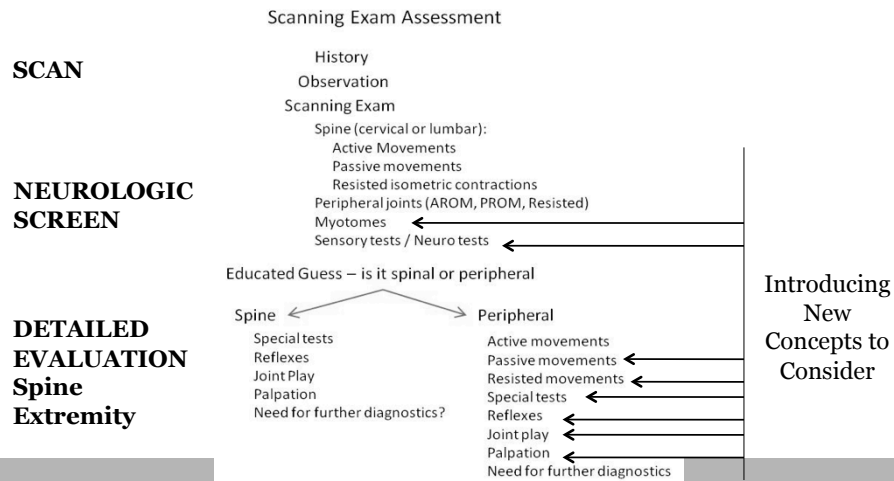
- ✦ L7/S1 Nerve Root impingement – acute on chronic

- (NOTE: when got up to leave – yelped
Change in muscle tone detected immediately
- left side L7)



Physical Therapy Assessments in Vet Medicine

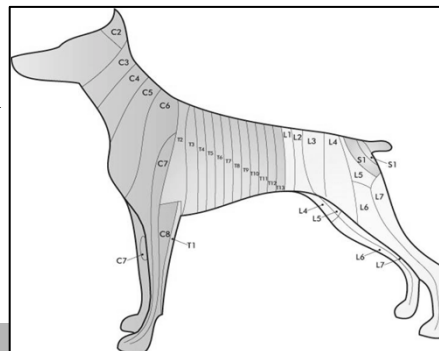
• A Physical Therapy Assessment Algorithm



Physical Therapy Assessments in Vet Medicine

• New Concepts & Considerations

- Myotome is a muscle or muscle group supplied primarily by one nerve root.
- Dermatome refers to an area of skin whereby sensation is supplied by one nerve root.
 - (Note, it has been shown that there is a 56% correlation with reduced nerve conduction in lick granuloma cases – Steiss et al 1995).



Physical Therapy Assessments in Vet Medicine



• New Concepts & Considerations

- Passive movement is not just range of motion (ROM), but also the evaluation of the quality of a movement.
- Passive movement does not only pertain to joint ROM, but to extensibility of the soft tissues as well (e.g. muscle stretching for diagnostic purposes).



Know your origins, insertions, & actions... to know how to stretch specific muscles.

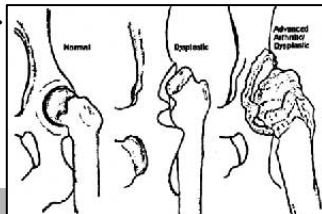
Physical Therapy Assessments in Vet Medicine



• New Concepts & Considerations

• A Capsular Pattern

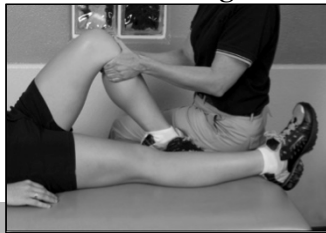- A 'capsular pattern of restriction' occurs when a lesion is of the joint capsule or when a total joint reaction is present that affects the joint capsule (e.g. as in osteoarthritis).
- A non-capsular pattern may indicate other restrictive lesions (e.g. ligamentous adhesions, internal derangement, or extra-articular lesions).



Physical Therapy Assessments in Vet Medicine



- **New Concepts & Considerations**
- **Joint Play = evaluation of the joint and ALL of it's movements**
 - Physiologic movements
 - Accessory movements
 - ✦ (i.e. Cranial, caudal, medial, & lateral glides)
 - At End Ranges and in Neutral



Physical Therapy Assessments in Vet Medicine



- **New Concepts & Considerations**
- **Joint Play → End Feels**
 - "End Feel":
 - ✦ The sensation in the tester's hands at the end of the motion
 - ✦ It can be used to identify the tissue that is limiting further motion

END FEELS	
Hard Capsular	Soft Capsular
Boney	Soft Tissue Opposition
Elastic	Springy
Spasm	Empty

Physical Therapy Assessments in Vet Medicine



- **CASE EXAMPLE** – Thunder – 10 yo MN Border Collie

- Referring Diagnosis:
 - ✦ ‘Unsure of the cause of lameness’
 - ✦ ‘Thinks it is shoulder’
- Subjective History:
 - ✦ Not moving or jumping well for a few months (in agility)
 - ✦ Last week became lame in RF

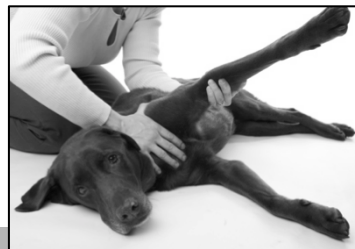

Physical Therapy Assessments in Vet Medicine



- **CASE EXAMPLE** – Thunder – 10 yo MN Border Collie

- R Shoulder Findings:
 - ✦ Pain on end range flexion & extension (pure glenohumeral joint). ROM normal (for a Border Collie)
 - ✦ Pain at end range abduction. ROM normal (for a Border Collie)



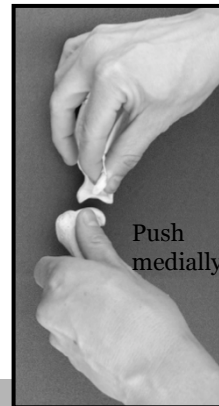
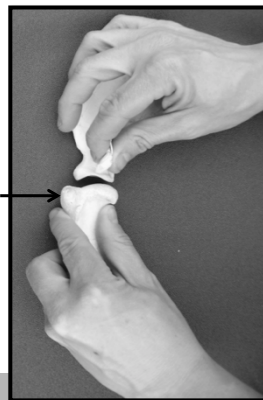
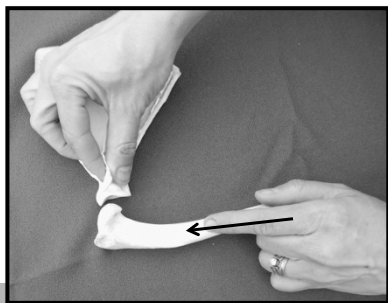
Physical Therapy Assessments in Vet Medicine



- **CASE EXAMPLE** – Thunder – 10 yo MN Border Collie

- R Shoulder Finding:

- ✦ Pain at end of each glide: cranial, caudal, & medial (okay lateral glide)
- ✦ Hard capsular end feels



Physical Therapy Assessments in Vet Medicine



- **CASE EXAMPLE** – Thunder – 10 yo MN Border Collie

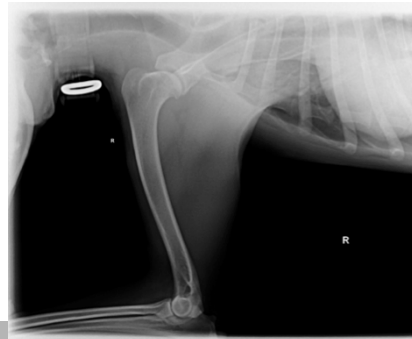
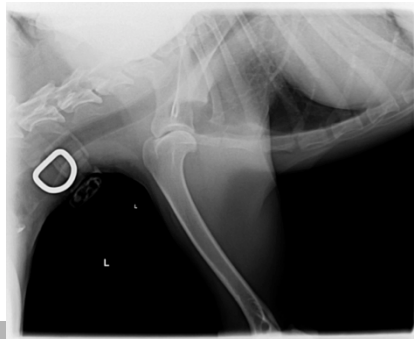- R Shoulder – supporting & additional findings

- ✦ MILD discomfort to palpation at supraspinatus tendon
- ✦ NO pain on palpation or stretch of biceps or caudal shoulder muscles
- ✦ NO pain on palpation of medial joint line
- ✦ No pain on palpation of the proximal humerus
- ✦ No pain with compression testing the glenohumeral joint
- ✦ MILD discomfort to deep palpation (cranial & medial sides) of the R elbow joint

Physical Therapy Assessments in Vet Medicine



- **CASE EXAMPLE** – Thunder – 10 yo MN Border Collie
 - Pathofunctional DIAGNOSIS
 - ✦ “Acute on chronic ‘flare’ of early shoulder osteoarthritis”
 - ✦ Subsequent radiographs confirmed



Physical Therapy Assessments in Vet Medicine



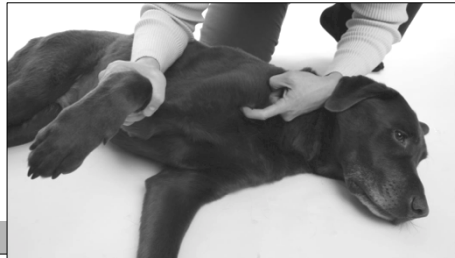- **New Concepts & Considerations**
 - Resisted Contractions
 - ✦ Injured muscles or tendons are painful when they contract
 - Special Tests
 - ✦ Incorporating ‘human’ tests – not yet utilized in vet medicine
 - McMurray’s test for stifle meniscus
 - Joint compressions for OCD lesions
 - Biomechanical analysis to create pressure tests for the medial coronoid or anconeal processes
 - 3/5 testing rule for detecting sacroiliac joint dysfunctions
 - Reflexes – using myotomal distribution
 - ✦ Reflexive muscles testing of particular muscle groups supplied by specific nerves

Physical Therapy Assessments in Vet Medicine



- **New Concepts & Considerations**

- Palpation
 - ✦ Being VERY specific over boney landmarks
 - ✦ Identifying teno-osseous junctions & musculotendinous junctions
 - ✦ Detecting abnormal muscle tone



Physical Therapy Assessments in Vet Medicine



- **Putting it all together**

- The cumulative results of all of the physical tests + subjective history.
- = The Pathofunctional Diagnosis



Physical Therapy Assessments in Vet Medicine



- Plenty to 'chew on'
 - Think of physiotherapy as being able to provide a second opinion
 - Think of physiotherapy as being able to augment veterinary medicine
 - ✦ Diagnostics & Treatment
 - Think of animal physiotherapist as allied health care professionals
 - Learn from each other!

Physical Therapy Assessments in Vet Medicine

- Tack för er uppmärksamhet!



Physical Assessment & Pathofunctional Diagnoses

Laurie Edge-Hughes, BScPT, MAnimSt(Animal Physio.), CAFCI, CCRT
Four Leg Rehab Inc – www.fourleg.com

Presented at the Colorado Veterinary Medical Association Conference, Keystone, Colorado, 2011.

With the splashy underwater treadmill, the colorful therapy balls, and gadgets that require electrodes, sunglasses, slings, or hypoallergenic gel, it could be easy to believe that ‘rehab’ is all about the toys! But that view-point could not be further from the truth! There is so much more to animal rehab than meets the eye!

Often the most important part of successful rehab is the assessment and diagnosis made by the rehab therapist. Physical therapists already possess unique assessment skills, and vets trained in animal rehab should have received additional training in physical therapy assessment skills in order to augment their veterinary diagnostics and create an appropriate rehab plan. The assessment techniques, enhanced deductive reasoning, and overall examination of function are what physical therapy and physical therapists are giving to the veterinary field.

The physical therapy assessment and diagnosis & how it differs from a veterinary assessment and diagnosis

Veterinary medicine tends to rely on what can be called a ‘patho-anatomical’ diagnosis, whereas physiotherapy and human medicine to a certain extent look at what can be termed a ‘patho-functional assessment’. The definitions are below:

Patho-anatomical diagnosis: This diagnostic perspective seeks the anatomical origination of the ‘problem’, relying some on clinical tests, and heavily on diagnostic tests. The primary goal is to ‘name the lesion’, with the subsequent thought process being how to reduce the lesion.

Patho-functional diagnosis: This diagnostic perspective not only seeks the anatomical origination of the ‘problem’ utilizing an assessment algorithm and the cumulative results from clinical tests, but also identifies the functional impairment, inter-relationships with other structures, repercussions, and potential biomechanical origins of the lesion. Thus the subsequent goal or thought process is not only how to best reduce the lesion (perhaps by rehabilitative treatments or by referral for surgery, etc), but also how to improve function.

Thinking outside the box to ‘name the lesion’

Several non-traditional sites and lesions can result in lameness, poor movement, reduced athletic performance, and postural alterations. Muscles can be the culprit of these ailments. Not only may muscle be directly implicated, as with a muscle strain or tendinopathy, but they may be creating functional impairments and pain when they are weak, tight/shortened, or riddled with myofascial trigger points.

Myofascial trigger points (MTrP) have been described as "...a hyper-irritable spot in skeletal muscle that is associated with a hypersensitive palpable nodule in a taut band. The spot is tender when pressed, and can give rise to characteristic referred pain, motor dysfunction, and autonomic phenomena..." (Simons, Travell, & Simons 1999) Several possible mechanisms can lead to the development of MTrPs, including low-level muscle contractions, uneven intramuscular pressure distribution, direct trauma, unaccustomed eccentric contractions, eccentric contractions in unconditioned muscle, and maximal or submaximal concentric contractions. Treating MTrPs can be difficult at best, but you cannot even begin if you are not looking for them in your clinical exam!

Weak muscles can create problems on many levels. Weak muscles do not cushion arthritic joints very well. Weak muscles can alter the proper biomechanical forces around a joint (e.g. weak abdominals can put strain on the lumbar spine). Weak muscles may also be a contributing factor to abnormal joint development, as in hip dysplasia. In many cases, general exercises do not specifically target and train individually weakened muscles. Thus, in order to improve pain and function, the isolated muscle weakness must be identified in order to directly treat it with specific, targeted, guided exercises.

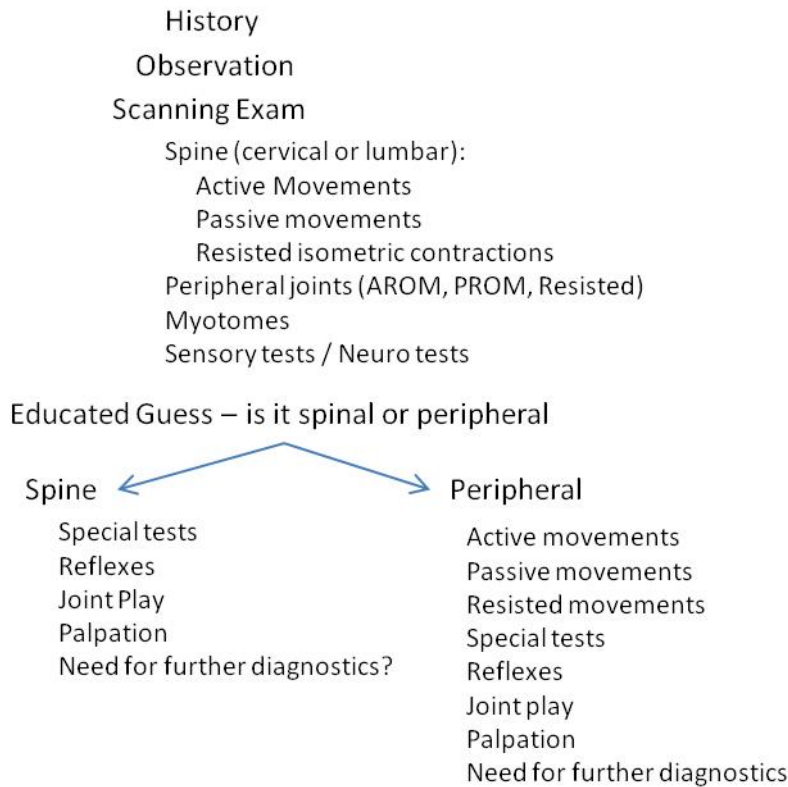
Tight, shortened muscles can also impact function as well. Often times upon testing, shortened muscles are also found to be weak. A shortened muscle quite simply has less biomechanical leverage and ability to create a strong muscle contraction. Short muscles can directly impact mobility within joints. This can then impact stride length and the quality of gait, which can lead to compensatory issues. The spine and axial skeleton is an area often affected by compensatory movement strategies, and therefore is an area in need of evaluation on every animal!

The axial skeleton consists of the joints in relation to the skull (i.e. temporomandibular joint), spine, ribs, and pelvis (i.e. the sacroiliac joint). Most of the veterinary industry recognizes the signs and symptoms of disc disease quite readily. Axial skeleton dysfunctions are not so readily acknowledged however. A 'dysfunction' in this region is a physical therapy term that implies that a joint is not moving appropriately, and is either termed as hypomobile or hypermobile. Dysfunctions can not only cause localized pain, but in some locations can refer pain down a limb. Thoracic limb lameness exams should include examination of the facet joints of the caudal cervical spine, the facet joints of the cranial thoracic spine, and the costotransverse, costovertebral, and costochondral joints of the cranial rib cage. Pelvic limb lameness exams need to incorporate evaluation of the lumbar facet joints and the sacroiliac joints. Not only should the joints in these regions be assessed, but also the soft tissues around these areas.

Algorithm for an orthopaedic rehab assessment

Figure 1 depicts a typical rehab evaluation and the physical evaluation tools that help to guide clinical reasoning for identification of the lesion and functional problems. Where an x-ray may find degenerative changes in the hip of a lame dog, a thorough physical evaluation will help to determine if that radiographic finding is the root of the lameness, impacted by the lameness, having a biomechanical impact on the true site of the lesion, or entirely coincidental to the lameness.

Scanning Exam Assessment



What this algorithm describes includes physical therapy principles, such as conducting a scanning exam. The scanning exam gives a cursory examination of all joints in all limb, as well as the spine, and includes a neurological screen. It then goes into further detail to examine either the spine or extremities.

What is a myotome? A myotome is a muscle or muscle group supplied primarily by one nerve root. A dermatome on the other hand, refers to an area of skin whereby sensation is supplied by one nerve root. The latter is particularly good to know, and attempt to correlate when one has a patient with a lick granuloma. (Note, it has been shown that there is a 56% correlation with reduced nerve conduction in lick granuloma cases – Steiss et al 1995).

Passive movement is not just range of motion (ROM), but also the evaluation of the quality of a movement. The quality of the movement can provide clues as to the health and functioning of the joint. Additionally, when joint restrictions are present, they can be categorized as being either a capsular pattern of restriction or a non-capsular pattern. A 'capsular pattern of restriction' occurs when a lesion is of the joint capsule or when a total joint reaction is present that affects the joint capsule (e.g. as in osteoarthritis). When a capsular or total joint reaction is present, a predictable pattern of restriction in passive ROM will occur. In human medicine, all joints have a documented capsular pattern of restriction. The same cannot be said of animal joints, but thanks to physical therapists who have evaluated end-feels on animal joints over a number of years; educated clinical guesses can be made as

to what the capsular patterns are for each animal joint. Thus, when a pattern of restriction is identified that does not fit with what is typically seen, this can be described as a non-capsular pattern and may indicate other restrictive lesions (e.g. ligamentous adhesions, internal derangement, or extra-articular lesions). It is also important to recognize that passive movement does not only pertain to joint ROM, but to extensibility of the soft tissues as well (e.g. muscle stretching for diagnostic purposes). The two are not always the same! Understanding muscle attachments, orientation, and actions is imperative to being able to assess for soft tissue lesions. Quite simply, much can be gained from a thorough evaluation of passive motion.

Resisted contractions of an injured muscle / tendon are uncomfortable. While we cannot request a muscle contraction against resistance of an animal patient, we can stretch a muscle and hold the limb in position as the animal tries to bring it back into a more comfortable position.

Special tests can those that we are familiar with already, such as the cranial drawer test to evaluate for cruciate ligament deficiency. Taking from human medicine, there are also tests that can be utilized to evaluate for meniscal derangement and presumed osteochondritis desiccans. Using biomechanical analysis and anatomical knowledge, other tests can be created to evaluate for elbow dysplasias, or sacroiliac joint pain for example as well.

Reflexive muscle contractions can be obtained from any muscle that you can 'hit' with a reflex hammer. This can be exceptionally useful when evaluating for lower motor neuron lesions, and makes knowledge of neuroanatomy (and myotomes) functionally relevant.

What is 'joint play' anyways? Joint play is the evaluation of the joint and all of its movements. It evaluated not only the physiologic motions of the joint (e.g. flexion and extension) but also the accessory motions within the joint (e.g. the motions that are necessary to movement, but not available volitionally, such as cranial and caudal glides or medial and lateral rotations at the stifle joint). The evaluation acknowledges the amount of 'play' (e.g. movement) within both the neutral position of the joint (mid-range) and end-ranges of the joint. Therapists are also trained to evaluate for 'end feels'. 'End feel' refers to the sensation in the tester's hands at the end of the motion, and can be used to identify the tissue that is limiting further motion. The sensations can be described as boney, hard capsular, soft capsular, soft tissue opposition, elastic, springy, etc. The appreciated end feel may or may not be appropriate for the joint being tested and for that specific direction of movement. It can be further quantified as coming in at the appropriate point in the range of motion, or too soon, or too late within the range.

Lastly is palpation. It looks at joint swelling or tenderness, being very specific as well at palpation of the soft tissue structures. Each extra-articular ligament that can be palpated should be palpated. And of great importance as well, is palpation of muscle-tendon units. Being able to palpate tendons at their most vulnerable points (the musculotendinous junction as well as the teno-osseous junction) provides an important diagnostic tool for any clinician.

A pathofunctional example

Take, for example, the case of a chronic partial CCL tear. We all understand that the joint is likely to be somewhat arthritic and fibrosed, but what about all of the compensations throughout the body that can impact function? For ease of discussion, one can look at this scenario from distal to proximal. With a chronic intra-articular issue of the stifle, the animal is not likely to put that joint into the end range of motion in either flexion or extension. The animal is likely to 'side-sit' to avoid full flexion. Over time, without regular positioning into a proper sit, the calcaneal tendon can become shortened to a point as to disallow full tarsus flexion. The side-sitting posture does not allow for symmetric use of the rear limbs when getting up from a sitting position or down to a sitting position. This may create an over dependence on the 'good' rear leg and both front legs in order to maneuver in and out of sitting. In this scenario, the animal could develop myofascial trigger points in his latissimus dorsi muscles and dysfunctions in his mid thoracic spine because of these compensations. As well, the unaffected limb may be at risk of injury due to perpetual overloading. Lack of full stifle extension can shorten the end stance phase of gait. In order to compensate, animal may try to gain some additional extension by hyperextending at the tarsal joint or through the lumbo-pelvic-hip region (e.g. as seen with dogs that externally rotate the limb and circumduct the leg as they walk). Hence secondary issues in the tarsus, sacroiliac joint, or lumbar spine may occur. While walking could be affected, often stance is as well, and even slight off-loading of the rear limb can result in a hypomobility in the caudal lumbar spine, or a kyphosis of the thoraco-lumbar region if the animal compensates by weight shifting forwards onto the front limbs. Furthermore, the off-loading requires overuse of the iliopsoas and Sartorius muscle groups on the affected limb in order to maintain the posture, which often results in the formation of myofascial trigger points and shortened muscles in these locations. Lastly, so as not to avoid the obvious, but in the case of the chronic partial cranial cruciate lesion, the musculature of the entire affected limb is likely to be atrophied and weaker, which can perpetuate the functional impairments brought about with this scenario, and potentially exacerbate comorbid areas of dysfunction that the animal is also afflicted with (eg. arthritic elbow joints). It can best be summed up with 'if an animal is lame somewhere, he is lame everywhere.' And as such, it is 'everywhere' that needs to be addressed!

Conclusion

Physical therapy in human medicine is a 'professional skill' for a reason. It is not just a summation of techniques and tools, but rather a professional discipline that utilizes problem solving skills, advanced manual skills, and a comprehensive functional physical examination in order to create a pathofunctional diagnosis. Perhaps next time you have the difficult patient in front of you; think of referring to a vet or physical therapist with animal rehab training to get a second diagnostic opinion, as well as to provide a therapeutic treatment option to complement your traditional veterinary plan.

References

1. Boyling & Jull (eds). *Grieve's Modern Manual Therapy*, Third Ed. Elsevier, New York, 2004.
2. Brotzman SB & Wilk KE. *Handbook of Orthopaedic Rehabilitation*, 2nd Ed. Mosby Elsevier, Philadelphia, 2007.
3. Butler D. *The Sensitive Nervous System*, NOI Publications, South Australia, 2000.

4. Jull G, McGowan C, Stubbs N. Module 1 – Approach to clinical practice, VETS7109 Principles of Animal Therapy Study Book. University of Queensland, 2005, pp 3 – 19.
5. Magee DJ. Orthopedic Physical Assessment, Fifth Edition. Saunders Elsevier, St Louis, 2008.
6. Maitland, Hengeveld, Banks, English. Maitland's Vertebral Manipulation, 7th Ed. Elsevier, New York, 2005.
7. Hengeveld & Banks. Maitland's Peripheral Manipulation, 4th Ed. Elsevier, New York, 2005.
8. Lee, D. The Thorax, An Integrated Approach. Dianne G Lee Physiotherapist Corporation, 2003.
9. McGowan, Goff, Stubbs (eds). Animal Physiotherapy. Blackwell Publishing, Oxford, 2007.
10. Rothstein, Roy, Wolf. The Rehabilitation Specialist's Handbook, 3rd Ed. F.A. Davis Company, Philadelphia, 2005.

CLINICAL REASONING FORM

Part A – To be completed following the subjective (owner and veterinarian) examination.

1. List the functional problems being experienced by the patient.

Cues: Is the animal lame, potential pain mechanisms, physical impairments, external influences i.e. farrier, rider – tack, racing surfaces and psychosocial issues such as sleeping environment, training-exercise regime, age, diet etc. Include the primary Veterinary diagnosis, including orthopaedic and systemic conditions.

2. Complete the following:

Primary hypothesis for source of symptoms	Patho/biological process	Likely physical findings
Alternative hypothesis (1) for source of symptoms	Patho/biological process	Likely physical findings
Alternative hypothesis (2) for source of symptoms	Patho/biological process	Likely physical findings

3. Indicate any sport specific, functional orientated or economic consequences of the functional problems.
4. Will you complete a full physical assessment today? Explain.

Part B – To be completed following objective assessment.

Provisional functional diagnosis	
Patho/biological mechanisms (outline)	
Physical impairments (outcome measures)	
Contributing factors including conformation, foot biomechanics (outcome measures)	
Any evident psychosocial factors: (outcome measures)	

MANAGEMENT

Goal of treatment for Day 1	
Treatment chosen	
Treatment effect	
Progression or plan for next treatment	
Home management plan	

*What are your **short term goals** for this patient?
Explain how these will be achieved and include the time period for each goal.*

*What are the **long term goals**?
Explain how these will be achieved and include the time period for each goal.*

POSSIBLE PROGNOSTIC FACTORS

FAVOURABLE	UNFAVOURABLE

What would constitute a successful outcome of treatment for this patient?

Approximately how many treatments over what time period do you estimate are required to achieve a successful outcome for this patient?

Number: _____ **treatments** **Time Period:** _____ **days / weeks / months**

REFLECTION

PART C (to be completed after initial full assessment)

- 1. Does your provisional hypothesis in part B match your primary hypothesis in part A?**

If not, what information can you now recognise that you initially missed, mis-interpreted, under or over-weighted?

PARD D (to be completed after 3-4 treatments)

DATE: _____

- 1. Outline any changes you have had to make your provisional diagnosis and explain your reasoning.**
- 2. Comment on the progress made by the patient with the short and long term goals?**

PART E (to be completed at discharge)

DATE: _____

- 1. Comment on the progress made by the patient with the short and long term goals?**
- 2. Highlight the hypotheses categories on the clinical pattern form (Part F) that were the strongest indicators of the patient's outcome and comment.**

PART F CLINICAL PATTERN FORM

Use the table to note the key features of the clinical presentation that would help you to recognise it again.

Clinical diagnosis:	
Area of Pain	
Behaviour of symptoms	
History	
Observation and movement patterns	
Neural system findings	
Muscular system findings	
Articular system findings	

Clinical reasoning report to referring veterinarian

CLINICAL REPORT (to be completed after three treatments)

Patient's Name: _____

Referred to Physiotherapy by: _____

Date: _____

Provisional Diagnosis (Veterinarian):

Functional Diagnosis (your provisional diagnosis):

The key assessment findings on Day 1 were:

Initial treatment consisted of:

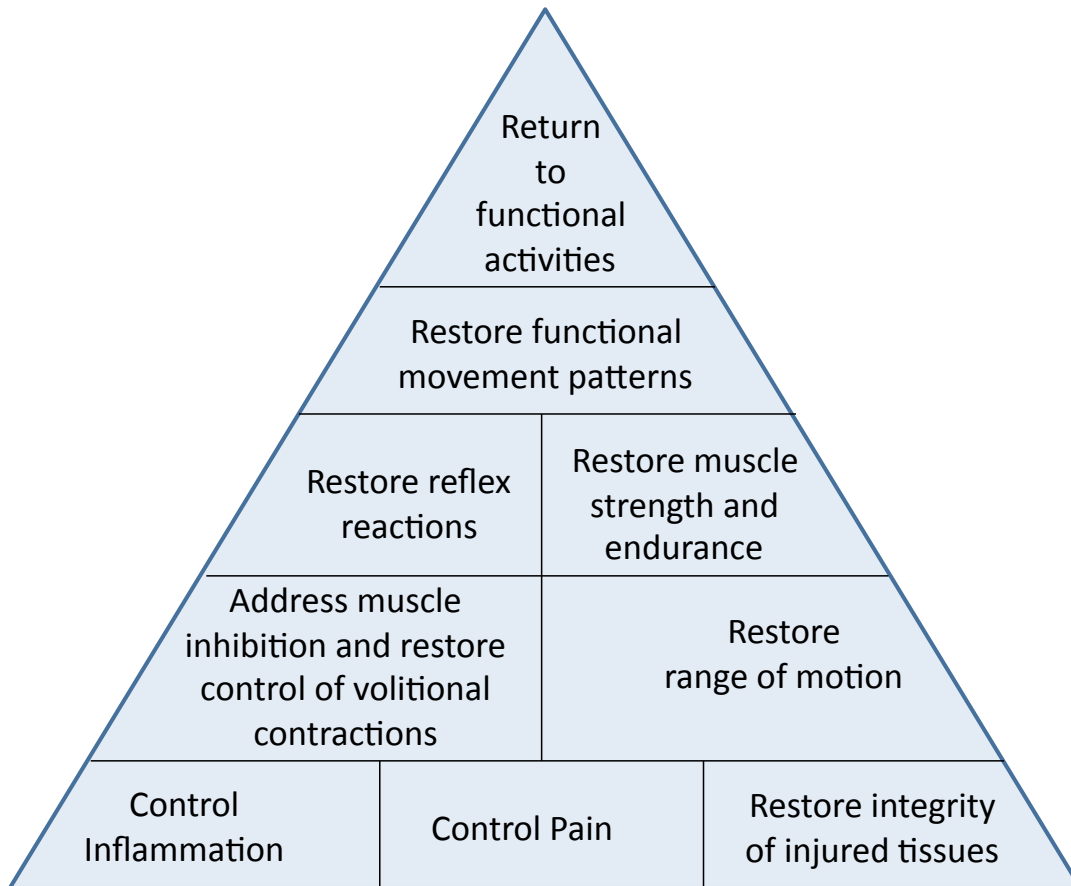
Which aimed to:

The effect of treatment was:

*Since the third treatment session, there has been **(circle)** no / some modification of the functional diagnosis. The physical assessment findings and/or treatment effects supporting this decision are:*

*The treatment approach has been **(circle)** modified or progressed by:*

The prognosis and plan for the next three treatments is as follows:



Rehabilitation pyramid (from Hertel, Deneger: A rehabilitation paradigm for restoring neuromuscular control following injury. Athl Ther Today, 3: 12 – 16; 1998)